



**PATIENT PRESENTING CLINICAL SIGNS**

Lola Funes History: Vomiting with specks of blood, which has worsened.

**SPECIES** Physical Examination: N/A.

Canine Urinalysis: N/A.

CBC: N/A.

**BREED** Serum Biochemistry: N/A.

Bulldog Radiographic Findings: N/A.

**SEX**

Female

**AGE**

11 years

**WEIGHT**

33 #

**INTERPRETED BY**

Remo Lobetti, BVSc,  
MMedVet (Med), PhD,  
Dipl. ECVIM

**ULTRASONOGRAPHIC EXAMINATION OF THE ABDOMEN**

**Urinary System**

Full urinary bladder with a normal appearance and thickness of the wall. Normal anechoic urine with no sediment or uroliths evident.

Normal trigone area, proximal urethra, and iliac blood vessels.

Normal iliac lymph nodes. Ureters not visualized.

Normal renal size with increased echogenic appearance, some loss of cortico-medullary differentiation, and normal pelvis and capsule.

**Reproductive System**

N/A.

**IMAGING PERFORMED BY**

Dr Paul Kim

**Adrenal Glands**

Normal shape, echogenic appearance, size, and position. Left 2.17 x 0.43 cm.

**HOSPITAL NAME**

Ridgefield Park Animal  
Hospital

**Spleen**

Normal size and echogenic appearance. Smooth homogenous parenchyma, smooth curvi-linear capsule, and normal vasculature. No evidence of inflammatory, neoplastic, infarction, or infiltrative changes noted.

**REFERRING VET**

Dr Paul Kim

**Liver**

Normal size, echogenic appearance, and portal markings. No nodules or masses evident. Full gall bladder containing small amount of hyperechogenic sediment. Normal thickness and appearance of the gall bladder wall. Normal bile duct.

**INVOICE**

302933

**Gastrointestinal**

**DATE**

4/28/22

Normal appearance of the duodenum, small intestine, ileo-cecal junction, and colon with no loss of layering, normal wall thickness and peristaltic activity, and no distension of the lumen. Severe thickening (1.7 cm) of the gastric wall with a diffuse mottled echogenic appearance and loss of layering.



**PATIENT** *Pancreas*

Lola Funes Normal size (1.3 cm) and echogenic appearance. Regular capsule. Normal echogenic appearance of the mesentery and fat surrounding the pancreas.

**SPECIES** *Free Abdomen*

Canine No mesenteric lymphadenomegaly.  
No ascites.

**BREED** **ULTRASONOGRAPHIC FINDINGS**

Bulldog

Primary Findings:

- Gastric thickening.

**SEX**

Female

Secondary Findings:

**AGE**

11 years

- Gall bladder sediment.
- Age-related renal changes.

**WEIGHT**

33 #

**INTERPRETATION OF THE FINDINGS & FURTHER RECOMMENDATIONS**

Likely etiologies for the appearance of the stomach would be neoplasia (lymphoma, carcinoma) and granulomatous gastritis with severe inflammatory bowel disease, ulceration, and *Helicobacter* gastritis, less likely differential diagnoses.

**INTERPRETED BY**

Remo Lobetti, BVSc,  
MMedVet (Med), PhD,  
Dipl. ECVIM

Further assessment would be FNA cytology of the stomach and gastroscopy with biopsies.

Specific therapy would be dependent on an etiological diagnosis. Symptomatic management would be gastric protectants (omeprazole and sucralfate) and anti-emetics.

**IMAGING PERFORMED BY**

Dr Paul Kim

**HOSPITAL NAME**

Ridgefield Park Animal  
Hospital

**REFERRING VET**

Dr Paul Kim

**INVOICE**

302933

**DATE**

4/28/22



**PATIENT**

Lola Funes

**IMAGES**

**Stomach**

**SPECIES**

Canine

**BREED**

Bulldog

**SEX**

Female

**AGE**

11 years

**WEIGHT**

33 #

**INTERPRETED BY**

Remo Lobetti, BVSc,  
MMedVet (Med), PhD,  
Dipl. ECVIM

**IMAGING PERFORMED BY**

Dr Paul Kim

**HOSPITAL NAME**

Ridgefield Park Animal  
Hospital

**REFERRING VET**

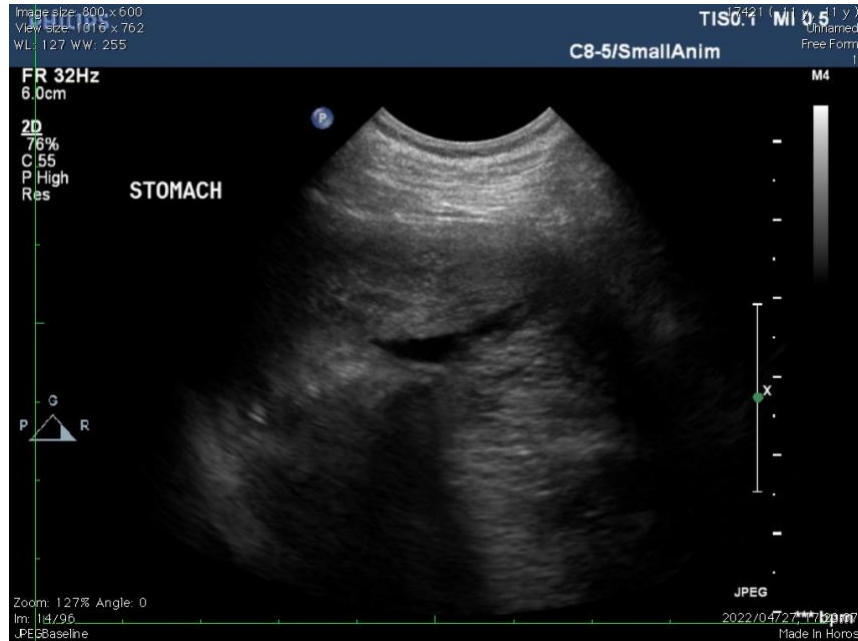
Dr Paul Kim

**INVOICE**

302933

**DATE**

4/28/22



**The information and recommendations provided are based on the images presented by the referring veterinarian. No evaluation can be communicated regarding pathology that was not visible in the image/video clips provided.**

Thank you for this referral. If the clinical or image interpretation does not parallel your findings or if I can be of any further assistance, please contact me.

**Remo Lobetti, BVSc, MMedVet (Med), PhD, Dipl. ECVIM (Internal Medicine)**  
[rlobetti@mweb.co.za](mailto:rlobetti@mweb.co.za)